

Thrombolysis during the endovascular treatment of iliac artery occlusions

Giuseppe Taddei, Paolo Tamellini, Faccioli Niccolo, Iannello Antonio

PURPOSE

The purpose of this study was to assess the possible therapeutic advantage of thrombolysis prior to recanalization of iliac occlusions with percutaneous treatment angioplasty and stenting.

MATERIALS AND METHODS

We retrospectively studied 28 cases of iliac occlusions in 26 patients, occurring over a six-year period. All patients suffered from claudication. Percutaneous treatments were performed using thrombolysis in 25 cases. The average duration of the infusion with urokinase-type plasminogen activator was 28.2 hours (range, 9–48 hours); total dose was 1,820,000 units per hour. The average duration of the follow-up was 46.6 months (range, 2–81 months).

RESULTS

In 21 of 25 cases (84%), we managed to correctly pass through the iliac occlusion using a guidewire and completed the thrombolysis. In all these cases, thrombolysis caused the complete dissolution of thrombi. All 21 cases with complete thrombolytic treatment had complete recanalization of the iliac axis. Twenty of these 21 cases (95%) were than successfully treated with percutaneous methodologies.

CONCLUSION

Thrombolysis may give an advantage in approaching the percutaneous treatment of atherosclerotic iliac arterial occlusions.

Key words: • thrombolytic therapy • iliac artery • digital subtraction angiography

Currently the number of aortofemoral bypasses performed for iliac occlusive arterial pathology is decreasing (1–4). The causes of this turnaround are the increase of the patients' mean age and the increased frequency of concurrent pathologies. Moreover, surgery, which for a long time has been considered as the treatment of choice for this pathology, has almost completely been replaced by less invasive methodologies such as endovascular treatments (5–9). The role of thrombolysis to treat the iliac arterial occlusive pathology on an atherosclerotic basis during endovascular surgery is controversial. Although comparing experiences is difficult, the results of pharmacologic thrombolysis to treat iliac arterial obstructions with regard to the different methodologies of treatment, to the drugs used and to other non-standardized variables seem encouraging (8). The first experiences with fibrinolytic therapy made us think it was unlikely that thrombolytic occlusions which had been present for longer than 1–2 weeks would adequately respond to these treatments. On the contrary, it was proved that injections of streptokinase or urokinase-type plasminogen activator (uPA) through the thrombus could also cause complete fibrinolysis in chronic occlusions (8). Recent thrombi (<15 days) are more sensitive to lysis, as shown by data from post-angioplasty thrombolysis (2, 5, 10). It is also true, however, that remarkable results may be achieved by using only percutaneous treatment angioplasty (PTA) associated with the stent technique (7).

The purpose of this study was to assess the possible therapeutic advantage of thrombolysis prior to recanalization of iliac occlusions with PTA and stenting.

Materials and methods

We retrospectively evaluated 28 cases of iliac occlusions treated in 26 patients (in two cases there was a re-occlusion) over a six-year period. Our cases did not have contraindications for thrombolysis. No patients were diabetic. The presumed etiologies for the iliac occlusions were plaque thrombosis for acute patients and chronic atherosclerotic disease for chronic patients. Absolute contraindications were established such as cerebrovascular event (including transient ischemic attacks within last 2 months), active bleeding diathesis, recent gastrointestinal bleeding (<10 days), neurosurgery within last 3 months, and trauma within last 3 months (10, 11); relative major contraindications were cardiopulmonary resuscitation within last 10 days, major nonvascular surgery or trauma within last 10 days, uncontrolled hypertension (180 mmHg systolic or 110 mmHg diastolic), puncture of non-compressible vessel, intracranial tumor, and eye surgery; minor contraindications were hepatic failure, particularly those with coagulopathy, bacterial endocarditis, pregnancy, and hemorrhagic retinopathy (10, 11).

From the Departments of Radiology (G.T.), and Surgery (P.T., I.A.), Sacro Cuore Hospital, Negrar, Italy; the Department of Radiology (F.N. ✉ niccolofcc@yahoo.com), G. B. Rossi University Hospital, Verona, Italy.

Received 12 August 2008; revision requested 12 November 2008; revision received 10 July 2009; accepted 27 July 2009.

Published online 4 February 2010
DOI 10.4261/1305-3825.DIR.2191-08.3

From the anamnesis and the morphologic aspect we systematically tried to identify the supposed period of the iliac occlusion. According to the literature (and recognizing difficulty of determining the onset of symptoms in patients with chronic arterial failure), we classified as *acute* the symptomatology which had suddenly arisen less than one week previously; as *subacute* the symptomatology which had arisen from one week to 3 months previously; as *chronic* the symptomatology which had arisen over 3 months previously. None of our patients had an acute course. We treated 6 patients (24%) suffering with a subacute course and 19 patients (76%) with a chronic course (occlusion dated from 3 months to 1 or more years previously). Based on Leriche-Fontaine classification (2), three patients were at stage II/a; 20 at II/b; 1 at III; 1 at IV.

Three of 28 cases were assessed not to be appropriate candidates for thrombolytic treatment because of overall condition, type of injury, associated pathology, or recent major abdominal surgery. We then performed percutaneous treatment using thrombolysis in 25 cases (23 patients; 21 males, 2 females). The mean age at the time of the first clinical examination was 67.0 years (range, 40–84 years). Risk factors included hypertension, smoking, and diabetes. In 8 cases the occlusion site was the common iliac artery (32%); in 11 cases it was the external iliac artery (44%); and in 6 cases it was the whole iliac axis (24%). Before treatment, all patients underwent complete digital subtraction angiography (DSA) of the aorta and lower limbs; this provided complete vascular representation and allowed classification of injuries as well as planning of an appropriate therapeutic approach (technique, access side, choice of the treatment timing and of the materials) We used the contralateral transfemoral access in 14 cases (56%), ipsilateral transfemoral access in 6 cases (24%), and access from both sides in 5 cases (20%).

The same access point of DSA was used for thrombolysis when possible. There were no technical failures in the ability to gain arterial access and begin uPA infusion. Patients' symptoms in the acute, subacute, and chronic occlusion groups involved claudication, rest pain, tissue necrosis, and threatened limbs. Catheters used in infusion var-

ied depending on the site and time of infusion. A 4 French infusion catheter (SOFT-VU Omni Flush, AngioDynamics, Queensbury, New York, USA), was placed via a 5 French vascular sheath (Cordis, Miami, Florida, USA; Med-iTech, Inc., Natick, Massachusetts, USA; or Cook, Inc., Bloomington, Indiana, USA) from either the ipsilateral or retrograde common femoral approach. Thrombolysis was classified as successful only when there was complete dissolution of thrombus, resulting in satisfactory blood flow through the vessel or graft. The lesion was presumably crossed through the central portion, and, despite the intrinsic difficulty of this operation, in all probability not sub-intimally.

The vessels were sometimes calcified, but this did not affect the success rate.

The pattern of treatment with a thrombolytic we used was modified slightly from that proposed by McNamara and Fisher (11). We administered uPA (Abbott Labs, Abbott Park, Illinois, USA) via 4 F intra-arterial catheter diluting 500,000 IU of uPA into 500 mL of physiologic solution (to obtain a concentration of 1,000 IU/mL), according to the following scheme: an initial load of 200 mL in the first hour (equivalent to 200,000 IU uPA, equivalent to 3,333 IU/min); subsequent infusion with 60 mL/hour (equivalent to 60,000 IU, equivalent to 1,000 IU/min), for a maximum period of 48–72 hours. Simultaneously, we infused sodium heparin via peripheral vein, beginning with 20,000 IU/ 24 h (diluting 20,000 IU in 500 mL of physiologic solution, we were able to infuse about 21 mL/hour). Dosage was then adjusted by keeping the activated partial thromboplastin time (aPTT) between 2 and 3 times over the basic value. The heparin infusion was stopped 48 hours after discontinuation of uPA. At the end of the heparin therapy, treatment consisted of an anti-aggregating therapy. The mean duration of the infusion with uPA was 28.2 hours (range, 9–48 hours). The total dose per patient was 1,820,000 units per hour. In three patients we had to stop thrombolysis since the endovascular treatment failed in a mean time of 15 hours. Three other patients not successfully treated with endovascular treatment were operated.

Monitoring of patients

Patients were monitored clinically, with attention to overall condition,

arterial pressure, the site of access, and other signs of hidden bleeding or ischemia.

From a technical point of view, we monitored the hematocrit, prothrombin time, aPTT, fibrinogen, and fibrin degradation products (10, 11). These examinations were performed just before beginning treatment, every 4 hours until we obtained an optimum heparin dosage, and subsequently every 8 hours until the heparin administration ended.

From a radiological point of view, we monitored the arterial recanalization and adjusted the position of the angiographic catheter when necessary at 4 hours after beginning the infusion and then every 4, 8, or 12 hours, depending on the length and difficulty of the procedure. The distal runoff was checked in each case after the treatments. The mean length of the iliac atherosclerotic arterial occlusions was 4.7 cm (range, 3–7 cm) for the common iliac artery, and 7.0 cm (range, 6–10 cm) for the external iliac artery.

The average hospital stay was 2.3 days (range, 2–5 days) for patients who completed thrombolysis. Post-treatment medication regimen was performed lifelong with acetylsalicylic acid or with clopidogrel, in case of intolerance at acetylsalicylic acid. Average duration of follow-up was 46.6 months (range, 2–81 months).

Results

The occlusion was identified in 16 cases (64%) on the right side and in 9 cases (36%) on the left. From a preliminary angiographic study, we found a good run-off (common and superficial patency of at least two leg femoral arteries) in 14 cases (56%), a fair run-off (occlusion of the superficial femoral artery with patency of the deep femoral artery) in 5 cases (20%), and a bad run-off (common femoral artery occlusion with stenosis of the deep femoral artery and/or patency of fewer than two leg arteries) in 4 cases (16%). The remaining two cases (8%) had bad run-off, and percutaneous treatment was followed immediately by surgery (thromboendarterectomy [TEA] of the femoral bifurcation).

No differences between results using contralateral transfemoral access and ipsilateral transfemoral access were found.

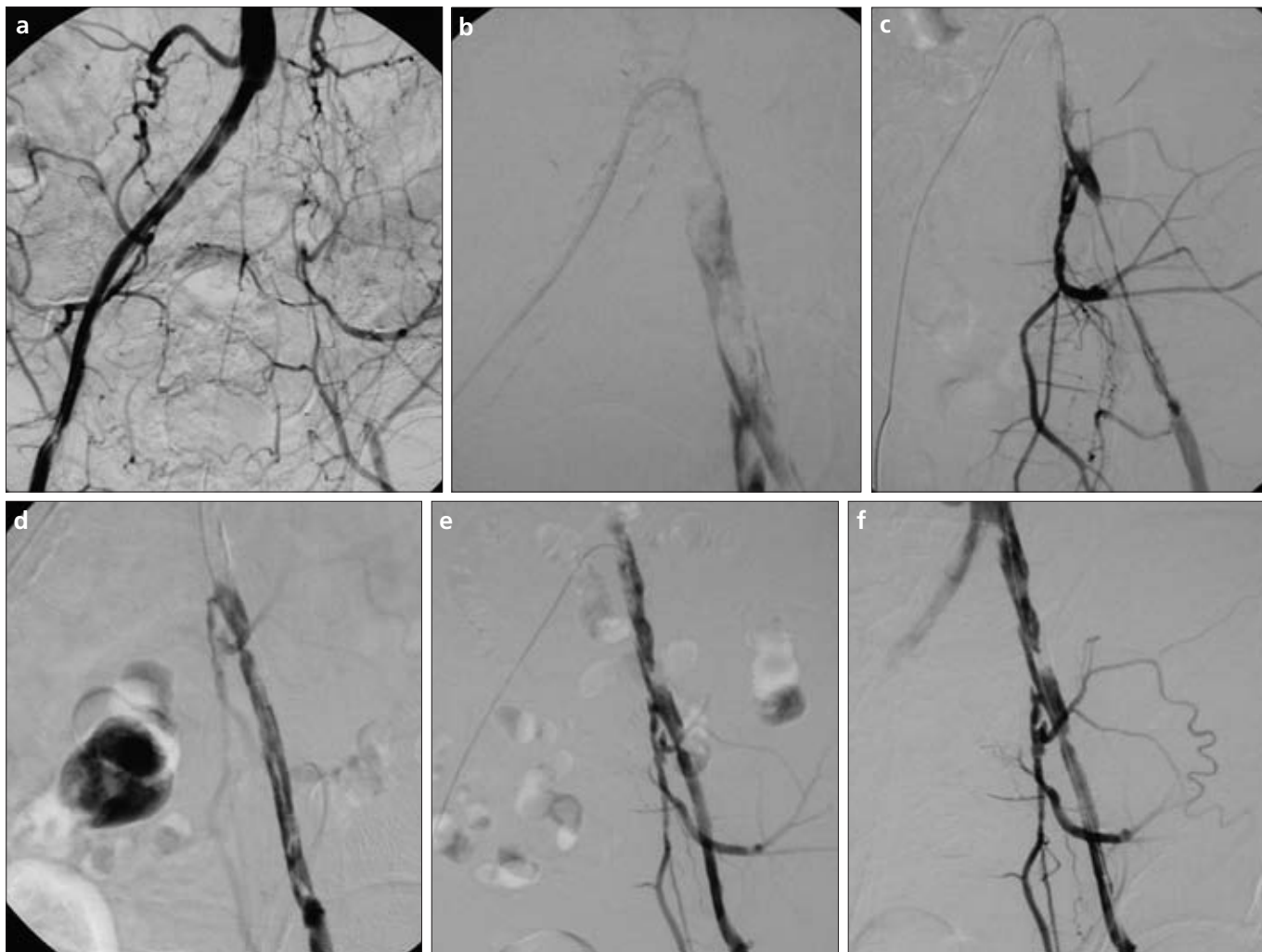


Figure. a–h. Angiograms of a 45-year-old male patient who was symptomatic for about a year. He has been walking with a limp for almost a month. Preliminary angiography (a) revealed occlusion of the common left iliac artery and left external iliac artery. We started the thrombolytic treatment (b) for the evidence of a thrombus. Angiogram performed after 24 hours (c) and after 34 hours (d) showed that the thrombus was reducing. Angiogram after 44 hours from thrombolysis (e) revealed the complete dissolution of the thrombus. Percutaneous treatment angioplasty and iliac stenting (f) were performed subsequently. Angiograms after stenting of the common iliac artery (g) and the external iliac artery (h) showed that the iliac axis was patent.

In all 21 patients for whom we completed the thrombolytic treatment, we identified complete recanalization of the iliac axis (Figure). The stenoses were treated after thrombolysis with

the following associated procedures: PTA alone in one case; PTA plus stenting in 16 cases (76.2%); PTA plus stenting and immediate femoral TEA in one case; femoral TEA alone in one case.

Early re-occlusion after thrombolysis plus PTA and stenting occurred, but complete recanalization was achieved with thrombolysis alone, and no further treatment was needed. Eventually,

in the very last case, the thrombolytic treatment revealed a wide dissection of the external iliac artery and of the common femoral artery as well. The patient underwent surgery (aortofemoral bypass).

Stents used included 8 Memotherm (Bard, Tempe, Arizona, USA), 2 Luminexx (Bard, Tempe, Arizona, USA), and 7 Palmaz (Johnson & Johnson Interventional Systems, Warren, New Jersey, USA).

We began thrombolytic treatment in 25 cases, and we were able to complete the treatment in 21 cases (84%): in three cases (12%) we discontinued the procedure because of subintimal catheter progression, and in one case we interrupted thrombolysis because of excessive alteration of the coagulation parameters.

In 21 of 25 cases (84%), we managed to correctly pass through the iliac occlusion by using a guidewire and we completed the thrombolysis. In all these cases (21/21), thrombolysis caused the complete dissolution of the thrombi. In 20 of 21 cases (95%), the occlusions turned into stenoses, which were successfully treated with percutaneous methodologies. In one case only, we chose not to perform a percutaneous recanalization, as the dissolution of the thrombi revealed a dissection involving the iliac axis and the common femoral artery. The patient underwent a surgical operation.

As a whole, we achieved complete recanalization and primary technical success with percutaneous methodology in 20 of 25 cases treated (80%) and in 20 of 21 in which we went through the injury to complete the thrombolysis.

Predictors of successful outcome were the immediate and easy passage of the lesion with a guidewire and a fast melting of the thrombi with an unmodified control after 4 hours.

Complications

One patient died from pulmonary embolism three months after the treatment.

Although thrombolytic therapy entails some risks when using urokinase, no side effects were observed with the use of uPA.

We identified a case of bleeding in the arterial access area, which required an early interruption (after 12 hours) of thrombolytic infusion. This did not

compromise the final result, nor did it require additional procedures.

In one case, thrombolysis had to be discontinued because of excessive alteration of the coagulation parameters.

We then observed two cases (8%) of peripheral embolization: the first was on the distal ramifications of the deep femoral artery (which was clinically irrelevant), while the second was on the tibioperoneal trunk and the anterior tibial artery (solved with suction thrombectomy).

Long-term results

After treatment all patients were included in a follow-up through color Doppler program at two months, six months, and one year. All patients underwent antiplatelet therapy. Among 21 patients with complete thrombolytic treatment, only one could not achieve a satisfactory result in terms of primary patency with percutaneous methodology (extended dissection of the external iliac artery and the common femoral artery).

Among 20 cases that were successfully recanalized, three were lost to follow-up (one died from pulmonary embolism three months after treatment; one due to an ictus 11 months after the procedure, and one because of a myocardial infarction 14 months after the procedure). We then proceeded with follow-up for 17 patients only.

We achieved a result of primary patency in 13 cases (82.4%) and secondary patency in 14 cases (88.2%). Among three cases with iliac reocclusion, two had early reocclusion (60 and 90 days after procedure, respectively). In one case, iliac patency could not be restored by percutaneous technique because of an unstable run-off (the external iliac artery and the common femoral artery tracts were too thin); so the patient was operated (aortobifemoral bypass). In the other case, we performed complete recanalization with thrombolysis only (patent 65 months after the procedure).

Discussion

Lately, endoluminal percutaneous techniques have become an increasingly popular form of treatment for peripheral arterial pathologies. Use of uPA thrombolytic therapy is not without risk. Most studies have reported a 2–7% major complication rate, with 1% being CNS-related (6, 7, 9, 11); we

did not have any CNS complications, probably because of the small cohort of patients, strict follow-up, and early termination of uPA administration at the first indication of change in hemocoagulation parameters.

For short iliac stenoses, angioplasty has become the standard treatment, with long-term patency results similar to those of surgery, giving patency rates well above 70% in 5 years (3, 12), therefore it has been deemed a first-choice methodology (5–8),

The introduction of stenting associated with PTA allowed improvement of already good results with short stenoses and the ability to achieve similarly good results for more extended stenoses. Memotherm and Luminexx stents were, to a great degree, equivalent, and were used for high radial force, flexibility, and good visibility; Palmaz stents were used for short lesions because they offer high precision in positioning and low cost.

Strecker et al. reported a 3-year patency of 92% for iliac stenoses treated with PTA plus stenting (4). The recanalization of the iliac occlusions is still debated, even though it reached a primary technical success in the percutaneous approach to iliac occlusions with PTA plus stenting close to 80% (9, 13, 14). Vorwerk et al., without performing the thrombolysis, reported a success in 81% of cases in terms of passing through the occlusion (9). Compared to their results, we achieved a technical primary success in 98% of cases and a primary 4-year patency in 78% of cases. In the same series by Vorwerk et al., the complication rate is 11.6% (5.8 % required an additional procedure), with 4% of patients experiencing early recurring thrombosis, 4.8% experiencing distal embolizations, and 2% experiencing inguinal hematomas (9).

According to the authors who do not perform thrombolysis, the success seems to be independent of length and site of the occlusion, while it seems to be connected with its duration: 3-month occlusion duration is indicated as discriminating (5–7).

Another parameter to take into account is the quality of the distal vascular bed (the so-called run-off): the highest number of acute reocclusions due to stent thrombosis was verified in patients with a bad run-off (6, 7).

To correct concomitant occlusive pathology in the intra-inguinal arterial district in the case of a bad run-off, the percutaneous procedure must be followed by surgery.

Several issues arise while performing a percutaneous treatment of the iliac occlusions: passing through the occluded iliac segment with a guidewire without performing thrombolysis, has a success rate close to 80% (9). In chronic occlusions, the addition of thrombolysis softens the thrombus, favoring the action of passing through the injury (15). It is also true that the combined action of thrombolysis and mechanical manipulation achieved with guidewire and catheter may cause the breakage of the superficial stratum of the thrombus, which is more organized, making contact with the underlying fresh thrombus easier. By using thrombolysis, very high rates of primary recanalization have been reported (98%) (9, 16, 17). We used multi-side hole catheters due to better and uniform sprinkling of the thrombus by the drug (9, 11, 16). We used urokinase because it achieves better results with fewer complications than other drugs (9, 11, 16). Thanks to our experience, we managed to go directly through the iliac occlusion with a guidewire without any mistakes on our part in 84% of cases: in one case we suspended the procedure because of coagulation issues, and in three cases (12%), we suspended the treatment because of a subintimal progression of the guidewire. This result may be unfavorably compared with the literature (16), where primary recanalization was unsuccessful in only 2% of cases. The difference is explained by the fact that we chose to take a particularly aggressive attitude in the "step-by-step" passing through the occlusion. It determined the subintimal progression of the guide in a higher percentage of cases (12%), and also it helped to restrain the infusion times with thrombolytic, allowing us to minimize the occurrence of major complications.

The second aspect to take into consideration for a successful recanalization of the occluded iliac arteries, is that according to the observations of Motarjeme et al., there is a variable degree of occlusive thrombosis at the beginning and at the end of the primitive stenotic atherosclerotic

injury (16). In this sense, following the methodology of TASC II (10) the thrombolysis may turn an extended occlusion into a shorter and more easily treatable stenotic injury. After thrombolysis the patient "changes category," being re-included into an easier injury typology which is more often percutaneously treated. As for long-term patency and complications, transforming an occlusion into a stenosis makes the patient feel like he/she belongs to a more favorable category (10, 16, 17).

According to our experience in 100% of cases where the infusion with uPA was completed, we obtained a restitution of a certain degree of patency, transforming all occlusions into stenoses, as did other authors (18, 19).

The third issue is maintenance of the vessel lumen after performing the iliac PTA. It is advisable to use the stent after iliac PTA in the following instances: cases with arterial dissection, cases with suspected elastic recoil of the wall, cases with acute occlusion during PTA, and cases with long iliac occlusions (5–7). Iliac stenting improves long-term results in comparison with simple PTA (2, 10).

It is reported that, with iliac occlusions, the treatment with PTA plus stenting gives better results than with simple iliac stenoses. Strecker et al., for example, in a series of 289 patients, after PTA and stenting reported a 3-year patency rate of 92% in iliac stenosis and only 63% in occlusions, a rate of thromboembolic complications of 0.9% in stenoses and 9% in occlusion, and early reocclusion rate from thrombolysis of the stent of 2.7% in stenoses and 15.2% in occlusions (4). This could be explained by the fact that occlusions are generally longer than stenoses, because of their overlapping part hit by a thrombus. A more serious wall trauma is then caused. So we need to use longer stents that, if the part hit by a thrombus passes through the stent links into the lumen, it may cause a thrombosis and/or an embolism or restenosis. As a matter of fact, a higher reocclusion percentage was reported when the stent was longer than 10 cm (5–7). In this case, thrombolysis may improve the result because it allows more selective use of stenting, requiring a shorter extension, resulting in a predictable improvement of long-term patency.

In our series of patients, with a mean follow-up of 46.6 months, the primary patency rate was 82.4% (with an early reocclusion rate due to thrombolysis of the stent of 11.8%); the secondary patency rate was 88.2%. The results of our experience seem to confirm that both the immediate complications and the long-term patency of the iliac occlusions treated with thrombolysis and PTA plus stenting may substantially overlap the ones reported in the literature covering simple stenose. We used the femoral approach because it is associated with fewer complications and because it is easier than other approaches (9, 11, 16). Endovascular treatment, moreover, preserves the vascular bed and does not interfere with possible subsequent surgery.

The limitation of our study was the small number of patients. Prospective randomized studies are needed to confirm our results.

In conclusion, the supporters of the primary stenting in the treatment of iliac occlusions assert that thrombolysis is a procedure which takes a longer time to be accomplished and is more expensive; furthermore, it may be dangerous and often additional stenting and PTA procedures must be performed. From our limited experience, we, like other authors, believe that thrombolysis may provide advantages in approaching percutaneous treatment of atherosclerotic iliac arterial occlusions—it may increase the chance of success in passing through the occlusion by using a guidewire; more patients will then undergo percutaneous treatment; and it may allow more precise treatment of the primitive stenotic injury by removing the area with an overlapping area under the thrombus. Thus, indications for PTA will be more accurate, and there will be fewer immediate complications; thrombolysis may allow a less extended stenting of the artery and the removal of the part hit by a thrombus of the injuries; furthermore, it will help to improve the long-term results which will be overlapping those reported in the literature regarding stenoses.

Acknowledgment

We thank Yves Doessant for his assistance in preparing the manuscript.

References

1. Becker GJ, Katzen BT, Dake MD. Non-coronary angioplasty. *Radiology* 1989; 170:403–412.
2. The STILE trial. Results of a prospective randomized trial evaluating surgery versus thrombolysis for ischemia of the lower extremity. *Ann Surg* 1994; 220:251–266.
3. Pozzi Mucelli F, Fisicaro M, Calderan L, et al. Percutaneous revascularization of femoropopliteal artery disease: PTA and PTA plus stent. Results after six years' follow-up. *Radiol Med* 2003; 105:339–349.
4. Strecker EP, Boos IBL, Hagen B, et al. Flexible tantalum stent for the treatment of iliac artery lesions: long-term patency, complications, and risk factors. *Radiology* 1996; 199:641–647.
5. Falkowski A, Poncyliusz W, Mokrzyński S, et al. Percutaneous endovascular recanalization of iliac artery. *Med Sci Monit* 2004; 10:42–45.
6. Carnevale FC, De Blas M, Merino S, et al. Percutaneous endovascular treatment of chronic iliac artery occlusion. *Cardiovasc Intervent Radiol* 2004; 27:447–452.
7. Berczi V, Thomas SM, Turner DR, et al. Stent implantation for acute iliac artery occlusions: initial experience. *J Vasc Interv Radiol* 2006; 17:645–649.
8. Korn P, Khilnani NM, Fellers JC, et al. Thrombolysis for native arterial occlusions of the lower extremities: clinical outcome and cost. *J Vasc Surg* 2001; 33:1148–1157.
9. Vorwerk D, Gunther RW, Schurmann K, et al. Primary stent placement for chronic iliac artery occlusions: follow-up results in 103 patients. *Radiology* 1995; 194:745–749.
10. Norgren L, Hiatt WR, Dormandy JA, et al. On behalf of the TASC II Working Group. Inter-Society Consensus for the Management of Peripheral Arterial Disease (TASC II). *J Vasc Surg* 2007; 45:5–67.
11. McNamara TO, Fischer JR. Thrombolysis of peripheral arterial and graft occlusions: improved results using high-dose urokinase. *AJR Am J Roentgenol* 1985; 144:769–775.
12. Kudo T, Chandra FA, Ahn SS, et al. Long-term outcomes and predictors of iliac angioplasty with selective stenting. *J Vasc Surg* 2005; 42:466–475.
13. Colapinto RF, Stronell RD, Johnston WK, et al. Transluminal angioplasty of complete iliac obstructions. *AJR Am J Roentgenol* 1986; 146:859–862.
14. Gupta AK, Ravmandalam K, Rao VRK, et al. Total occlusion of iliac arteries: results of balloon angioplasty. *Cardiovasc Intervent Radiol* 1993; 16:165–177.
15. Park KB, Do YS, Kim JH, et al. Stent placement for chronic iliac arterial occlusive disease: the results of 10 years experience in a single institution. *Korean J Radiol* 2005; 6:256–266.
16. Motarjeme A, Gordon GI, Bodenhausen K, et al. Thrombolysis and angioplasty of chronic iliac artery occlusions. *J Vasc Interv Radiol* 1995; 6:66–72.
17. Blum U, Gabelmann A, Redecker M, et al. Percutaneous recanalization of iliac artery occlusion: results of a prospective study. *Radiology* 1993; 189:536–540.
18. Ouriel K, Veith F, Sasahara A, et al. A comparison of recombinant urokinase with vascular surgery as initial treatment for acute arterial occlusion of the legs. Thrombolysis or Peripheral Arterial Surgery (TOPAS) Investigators. *N Engl J Med* 1998; 338:1105–1111.
19. Wholey MH, Maynar MA, Wholey MH, et al. Comparison of thrombolytic therapy of lower-extremity acute, subacute, and chronic arterial occlusions. *Cathet Cardiovasc Diagn* 1998; 44:159–169.